

## ... Sujet de nombreuses publications scientifiques

1. Posterior jaws rehabilitated with partial prostheses supported by 4.0 x 4.0 mm or by longer implants: Four-month post-loading data from a randomised controlled trial.

Esposito M, Barausse C, Pistilli R, Checchi V, Diazi M, Gatto MR, Felice P. *European Journal of Oral Implantology* 2015; 8(3):221-30.

2. Posterior jaws rehabilitated with partial prostheses supported by 4.0 x 4.0 mm or by longer implants: One-year post-loading results from a multicenter randomised controlled trial. Felice P, Checchi L, Barausse C, Pistilli R, Sammartino G, Masi I, Ippolito DR, Esposito M. *European Journal of Oral Implantology* 2016; 9(1):35-45.

3. Posterior jaw rehabilitation using partial prostheses supported by implants 4.0 x 4.0 mm or longer: three-year post-loading results of a multicentre randomised controlled trial. Barausse C, Felice P, Pistilli R, Buti J, Esposito M. *Clinical Trials in Dentistry* 2019; 1(1):25-36.

4. Four mm-long versus longer implants in augmented bone in atrophic posterior jaws: 4-month post-loading results from a multicentre randomised controlled trial. Esposito M, Zucchelli G, Barausse C, Pistilli R, Trullenque-Eriksson A, Felice P. *European Journal of Oral Implantology* 2016; 9(4):393-409.

5. Four mm-long versus longer implants in augmented bone in posterior atrophic jaws: One year post-loading results from a multicentre randomised controlled trial. Bolle C, Felice P, Barausse C, Pistilli R, Trullenque-Eriksson A, Esposito M. *European Journal of Oral Implantology* 2018; 11(1):31-47.

6. Four mm-long versus longer implants in augmented bone in posterior atrophic jaws: Three-year post-loading results from a multicentre randomised controlled trial. Felice P, Barausse C, Pistilli R, Kalemaj Z, Esposito M. *Clinical Trials in Dentistry* 2020; 2(1):5-2.

7. Rehabilitation of the atrophic posterior mandible with short (4-mm) implants: a case report. Pistilli R, Barausse C, Checchi L, Felice P. *International Journal of Periodontics and Restorative Dentistry* 2014; (5):713-8.

8. Minimally invasive fixed rehabilitation of an extremely atrophic posterior mandible using 4-mm-ultrashort implants: a 7-year follow-up case report. Pistilli R, Zucchelli G, Barausse C, Bonifazi L, Karaban M, Gasparro R, Felice P. *International Journal of Periodontics and Restorative Dentistry* 2020; 40(6):e3-e8.

9. A Minimally Invasive Approach Using a 4-mm Implant Without Extraction of Impacted Maxillary Canine: Four-Year Postloading Results. Felice P, Barausse C, Stefanini M, Pistilli R, Zucchelli G. *International Journal of Periodontics and Restorative Dentistry* 2017; 37(6):819-824.

10. Four-mm-supershort post-extractive immediately provisionalized implant in a minimally invasive rehabilitation approach avoiding extraction of the impacted maxillary canine: a 2-year follow-up case report. Barausse C, Gasparro R, Berti C, Menetti M, Colombelli F, Felice P. *International Journal of Periodontics and Restorative Dentistry* 2021; 41(5):727-732.

11. Minimally Invasive Fixed Rehabilitation of a Totally Edentulous Severely Atrophic Mandible with 4-mm Ultrashort Immediately Loaded Implants: A Case Report. Pistilli R, Barausse C, Gasparro R, Berti C, Felice P. *International Journal of Periodontics and Restorative Dentistry* 2020; 40(4):549-559.

12. Minimally invasive rehabilitation of a severely atrophic and fully edentulous maxilla using 4-mm-ultrashort implants: a case report with 1-year follow-up. *Oral and Maxillofacial Surgery Cases* 2020; 6(3):1-6.

13. Crestal or 1.5 mm subcrestal positioning of transmucosal dental implants with cemented or screw-retained crowns in posterior jaws: 4-month data from a single-centre randomised controlled trial. Barausse C, Esposito M, Colombelli F, Bellini P, Buti J, Felice P. *Clinical Trials in Dentistry* 2020; 2(2):19-33.

14. One-Piece Implants with Smooth Concave Neck to Enhance Soft Tissue Development and Preserve Marginal Bone Levels: A Retrospective Study with 1- to 6-Year Follow-Up. Axiotis JP, Nuzzolo P, Barausse C, Gasparro R, Bucci P, Pistilli R, Sammartino G, Felice P. *Biomed Research International* 2018.

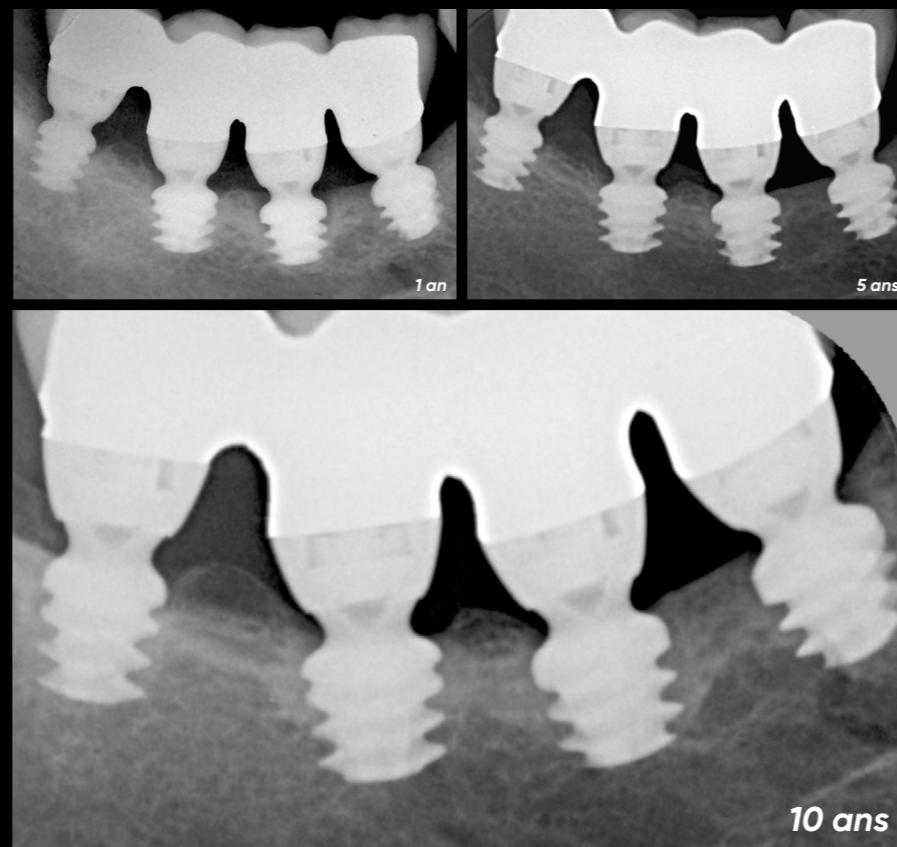
## twinkon®

Résultats à 5 ans\*

Taux de survie : **99,4%**

Taux de satisfaction : **98,6%**

\* Étude rétrospective sur 70 patients



\*Jean-Pierre Axiotis, Paolo Nuzzolo, Carlo Barausse, Roberta Gasparro, Paolo Bucci, Roberto Pistilli, Gilberto Sammartino, Pietro Felice - One-Piece Implants with Smooth Concave Neck to Enhance Soft Tissue Development and Preserve Marginal Bone Levels: A Retrospective Study with 1 to 6 year Follow-up Hindawi - Biomed Research International - Volume 2018, Article ID 2908484, 7pages

Les produits présentés sont des Dispositifs Médicaux de classe IIb et, à ce titre, sont porteurs du marquage CE (CE0459) conformément à la Directive 93/42/CEE. En France, ces dispositifs médicaux ne sont pas soumis au régime de remboursement de la Sécurité Sociale. Il est possible que les dispositifs médicaux présentés ne soient pas disponibles à la vente dans tous les pays. En cas de doute ou pour tout complément d'information, veuillez-vous rapprocher du service commercial de Global D.

 **GlobalD**

ZI de Sacuny  
118 Avenue Marcel Mérieux  
Brignais - France

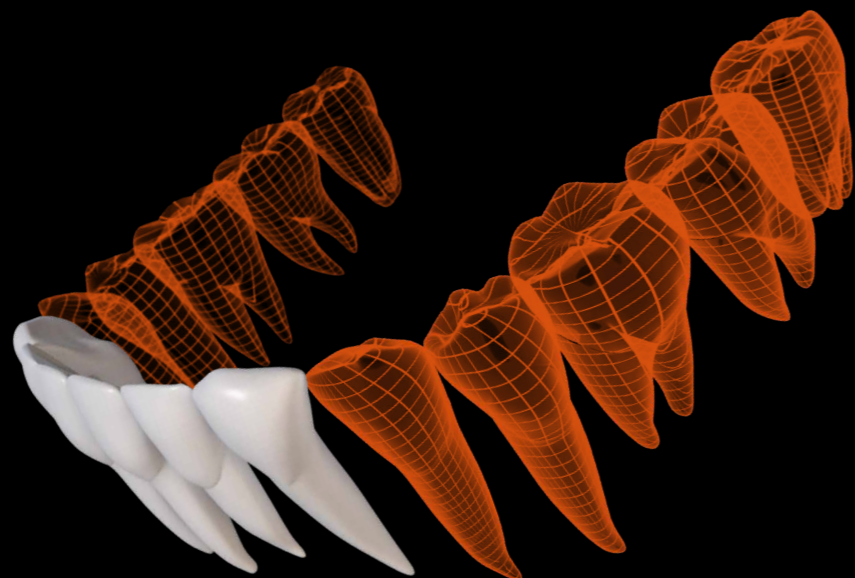
Tél. +33 (0)4 78 56 97 00  
fax +33 (0)4 78 56 01 63

[www.globald.com](http://www.globald.com)

# twinkon® 4

L'implant **ultra court**  
breveté ...

.... pour **préserver le capital osseux résiduel** dans le temps

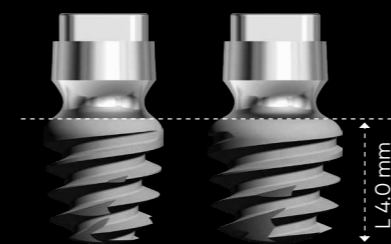


## O-ring conjonctif


Le **col lisse transmuqueux concave** de l'implant twinkon<sup>®</sup>4, surmonté d'une **connectique de type cône externe** à 5°, permet d'obtenir une cicatrisation. Ce col concave permet d'obtenir une cicatrisation muqueuse dès la phase initiale d'ostéointégration. Une fois stabilisé, le joint conjonctif jouera naturellement le rôle de **barrière de protection**.\*

\* Etude sur beagle réalisée par les Drs Bolle C 1-2, Exbrayat P 2, Gustin M.-P. et Grosgeat B 1-2 en collaboration avec le Dr D. Fau 3 (Méthode d'analyse : histologie, os non décalcifié, cutting-grinding)

- **Deux diamètres** : 4 & 4.5 mm
- **Longueur 4 mm**



- Ancillaire spécifique comprenant **des forets dédiés**, à butées fixes
- **11 ans de suivi clinique**



### Indications

Traitement des secteurs molaires mandibulaires sévèrement atrophiés



EAO  
EUROPEAN ASSOCIATION FOR ORAL IMPLANT DENTISTRY



**1st prize oral communication** for Clinical Research in Implant Dentistry: Surgery - EAO 2016 - Paris <sup>(1)</sup>

**1st prize oral communication** for Clinical Research in Implant Dentistry: Surgery - EAO 2017 - Madrid <sup>(2)</sup>

**Best Oral Clinical Presentation** for the 2021 AO Annual Meeting <sup>(3)</sup>

(1) « Posterior jaws rehabilitated with partial prostheses supported by 4x4mm or by longer implants : a 1-year post-loading randomised controlled trial". (P. Felice)

(2) « 4mm-long versus longer implants in augmented bone in atrophic jaws - 4-month loading RCT results". P. Felice (Italy)

(3) For presentation on 4mm Supershort Implants Compared with Longer Implants Placed in Reconstructed Posterior Atrophic Jaws : 3 Year Results from an RCT