

... Oggetto di **numerose pubblicazioni scientifiche**



1. **Posterior jaws rehabilitated with partial prostheses supported by 4.0 x 4.0 mm or by longer implants: Four-month post-loading data from a randomised controlled trial.**

Esposito M, Barausse C, Pistilli R, Checchi V, Diazi M, Gatto MR, Felice P. *European Journal of Oral Implantology* 2015; 8(3):221-30.

2. **Posterior jaws rehabilitated with partial prostheses supported by 4.0 x 4.0 mm or by longer implants: One-year post-loading results from a multicenter randomised controlled trial.** Felice P, Checchi L, Barausse C, Pistilli R, Sammartino G, Masi I, Ippolito DR, Esposito M. *European Journal of Oral Implantology* 2016; 9(1):35-45.

3. **Posterior jaw rehabilitation using partial prostheses supported by implants 4.0 x 4.0 mm or longer: three-year post-loading results of a multicentre randomised controlled trial.** Barausse C, Felice P, Pistilli R, Buti J, Esposito M. *Clinical Trials in Dentistry* 2019; 1(1):25-36

4. **Four mm-long versus longer implants in augmented bone in atrophic posterior jaws: 4-month post-loading results from a multicentre randomised controlled trial.** Esposito M, Zucchelli G, Barausse C, Pistilli R, Trullenque-Eriksson A, Felice P. *European Journal of Oral Implantology* 2016; 9(4):393-409.

5. **Four mm-long versus longer implants in augmented bone in posterior atrophic jaws: One year post-loading results from a multicentre randomised controlled trial.** Bolle C, Felice P, Barausse C, Pistilli R, Trullenque-Eriksson A, Esposito M. *European Journal of Oral Implantology* 2018; 11(1):31-47.

6. **Four mm-long versus longer implants in augmented bone in posterior atrophic jaws: Three-year post-loading results from a multicentre randomised controlled trial.** Felice P, Barausse C, Pistilli R, Kalemaj Z, Esposito M. *Clinical Trials in Dentistry* 2020; 2(1):5-2

7. **Rehabilitation of the atrophic posterior mandible with short (4-mm) implants: a case report.** Pistilli R, Barausse C, Checchi L, Felice P. *International Journal of Periodontics and Restorative Dentistry* 2014; (5):713-8.

8. **Minimally invasive fixed rehabilitation of an extremely atrophic posterior mandible using 4-mm-ultrashort implants: a 7-year follow-up case report.** Pistilli R, Zucchelli G, Barausse C, Bonifazi L, Karaban M, Gasparro R, Felice P. *International Journal of Periodontics and Restorative Dentistry* 2020; 40(6):e3-e8

9. **A Minimally Invasive Approach Using a 4-mm Implant Without Extraction of Impacted Maxillary Canine: Four-Year Postloading Results.** Felice P, Barausse C, Stefanini M, Pistilli R, Zucchelli G. *International Journal of Periodontics and Restorative Dentistry* 2017; 37(6):819-824.

10. **Four-mm-supershort post-extractive immediately provisionalized implant in a minimally invasive rehabilitation approach avoiding extraction of the impacted maxillary canine: a 2-year follow-up case report.** Barausse C, Gasparro R, Berti C, Menetti M, Colombelli F, Felice P. *International Journal of Periodontics and Restorative Dentistry*. *International Journal of Periodontics and Restorative Dentistry* 2021; 41(5):727-732

11. **Minimally Invasive Fixed Rehabilitation of a Totally Edentulous Severely Atrophic Mandible with 4-mm Ultrashort Immediately Loaded Implants: A Case Report.** Pistilli R, Barausse C, Gasparro R, Berti C, Felice P. *International Journal of Periodontics and Restorative Dentistry* 2020; 40(4):549-559

12. **Minimally invasive rehabilitation of a severely atrophic and fully edentulous maxilla using 4-mm-ultrashort implants: a case report with 1-year follow-up.** *Oral and Maxillofacial Surgery Cases* 2020; 6(3):1-6

13. **Crestal or 1.5 mm subcrestal positioning of transmucosal dental implants with cemented or screw-retained crowns in posterior jaws: 4-month data from a single-centre randomised controlled trial.** Barausse C, Esposito M, Colombelli F, Bellini P, Buti J, Felice P. *Clinical Trials in Dentistry* 2020; 2(2):19-33

14. **One-Piece Implants with Smooth Concave Neck to Enhance Soft Tissue Development and Preserve Marginal Bone Levels: A Retrospective Study with 1- to 6-Year Follow-Up.** Axiotis JP, Nuzzolo P, Barausse C, Gasparro R, Bucci P, Pistilli R, Sammartino G, Felice P. *Biomed Research International* 2018.


twinKon®

Risultati twinKon® a 5 anni*

Tasso di sopravvivenza : **99,4%**

Tasso di soddisfazione : **98,6%**

* Studio retrospettivo su 70 pazienti



*Jean-Pierre Axiotis, Paolo Nuzzolo, Carlo Barausse, Roberta Gasparro, Paolo Bucci, Roberto Pistilli, Gilberto Sammartino, Pietro Felice - One-Piece Implants with Smooth Concave Neck to Enhance Soft Tissue Development and Preserve Marginal Bone Levels: A retrospective Study with 1 to 6 year Follow-up Hindawi - Biomed Research International - Volume 2018, Article ID 2908484, 7pages

I prodotti presentati sono dispositivi medici di classe I, IIa e IIb e, come tali, recano il marchio CE (CE 0459) in conformità alla direttiva 93/42/CEE. È possibile che i dispositivi medici presentati non siano disponibili per la vendita in tutti i paesi. In caso di dubbi, contattare l'ufficio vendite Tekka Italia.




ZI de Sacuny
118 Avenue Marcel Mérieux
Brignais - France

Tél. +33 (0)4 78 56 97 00
fax +33 (0)4 78 56 01 63

www.globald.com

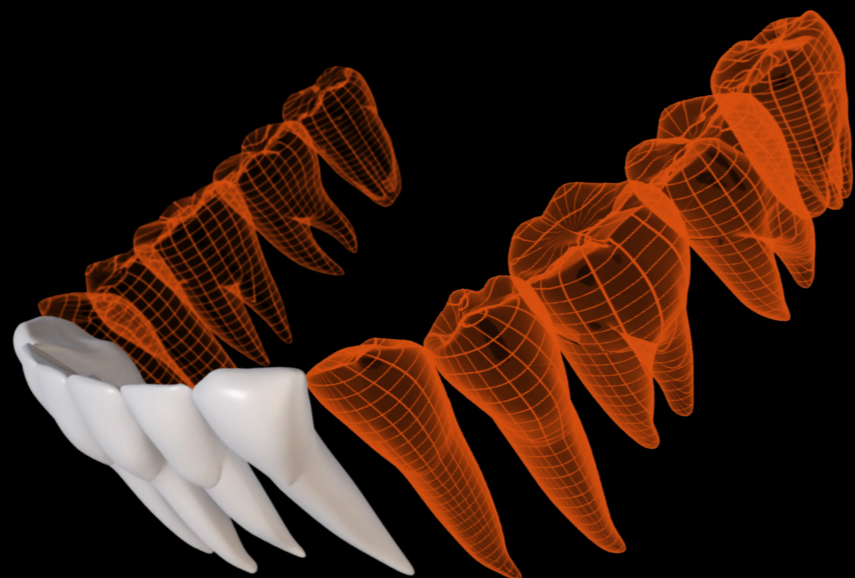
twinKon® 4

L'impianto brevettato
ultra corto ...



OODPR-TWK4-A5-IT-1-23

.... preservare il capitale osseo residuo nel tempo



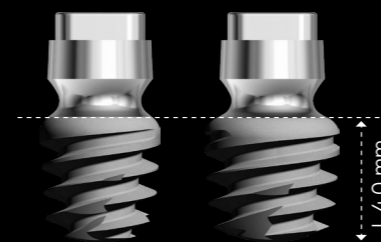
Indicazioni
Trattamento di settori molari mandibolari gravemente atrofizzati

O-ring connettivo


Il **colletto liscio transmucoso concavo** dell'impianto twinKon®, sormontato da un elemento di **connessione conico esterno**, permette la guarigione. Questo colletto concavo permette la guarigione della mucosa fin dalla fase iniziale dell'osteointegrazione. Una volta stabilizzato, il tessuto connettivo agirà come una **barriera protettiva**.*

* Studio su beagle realizzato dal Dr. Bolle C.1-2, Dr. Exbrayat P. 2, Dr. Gustin M. P. e Dr. Grosgeat B. 1-2 in collaborazione con il Dr. D. Fau 3 (Metodo di analisi: istologia, osso non decalcificato, cutting-grinding)

- **Due diametri** : 4 e 4.5 mm
- **Lunghezza 4 mm**



- Apparecchiature ausiliarie specifiche, tra cui **frese dedicate** con arresti fissi
- **11 anni di follow-up clinico**



EAO
EUROPEAN ASSOCIATION FOR ORAL IMPLANT DENTISTRY



1st prize oral communication for Clinical Research in Implant Dentistry: Surgery - EAO 2016 - Paris ⁽¹⁾

1st prize oral communication for Clinical Research in Implant Dentistry: Surgery - EAO 2017 - Madrid ⁽²⁾

Best Oral Clinical Presentation for the 2021 AO Annual Meeting ⁽³⁾

(1) « Posterior jaws rehabilitated with partial prostheses supported by 4x4mm or by longer implants : a 1-year post-loading randomised controlled trial". (P. Felice)

(2) « 4mm-long versus longer implants in augmented bone in atrophic jaws - 4-month loading RCT results". P. Felice (Italy)

(3) For presentation on 4mm Supershort Implants Compared with Longer Implants Placed in Reconstructed Posterior Atrophic Jaws : 3 Year Results from an RCT